

# Autoimmune encephalitis

## Laboratory diagnostics for the detection of anti-neuronal autoantibodies

In recent years, new forms of encephalitis caused by antibodies directed against the nervous system have been identified. Knowledge of these encephalitides has led to the development of diagnostic and therapeutic measures which would have been unimaginable only a short time ago. The disease spectrum is wide and encompasses movement disorders, demyelinating diseases, epilepsy, psychoses and dementia. The most important evidence for correct diagnosis is provided by blood or cerebrospinal fluid (CSF) testing for the underlying pathogenic autoantibodies.

The best known and most frequent autoimmune encephalitis is anti-NMDA receptor encephalitis. Here, autoantibodies are formed against a glutamate receptor present on the nerve cells, glutamate receptor type NMDA. The disease affects mainly relatively young persons and women more often than men. A prodromal phase with headaches or malaise is followed by a schizophreniform syndrome. Patients are admitted into psychiatry. As the disease progresses, the majority develops epileptic seizures, hyperkinesia mainly in the face and vegetative disorders with blood pressure crises or asystole. Some patients require mechanical ventilation in intensive care units for months. However, if a sufficiently aggressive immunotherapy is promptly initiated, prognosis is so good that the majority can go back to school or work.

The discovery of these autoimmunologically caused encephalitides had extensive consequences especially in the areas of neurology and psychiatry. On the one hand, a distinct novel disease could be identified, which had previously been misinterpreted as drug-induced psychosis, non-infectious encephalomyelitis, encephalitis of unknown etiology or dissociative disorder, and consequently not treated with immunotherapeutic measures. On the other hand, the discovery has encouraged researching physicians and thus led to the discovery of a large number of further antibodies.

In the meantime it could be proven that NMDA receptor antibodies are directly pathogenic. Mono-

clonal antibodies from patients with anti-NMDA receptor encephalitis (Fig. 1A) were recombinantly produced by means of molecular biological methods. On hippocampus neurons, it could be shown that the antibodies lead to an internalisation of the NMDA receptor which is then no longer available for the synaptic transmission (Fig. 1B: Kreye et al. 2016, BRAIN). This mechanism shows firstly that patients with this antibody type carry the risk of developing neuropsychiatric disorders, and secondly it provides the long-sought for scientific argument for an in part aggressive immunotherapy for these patients. The binding of the antibodies to their target protein is also used for the diagnostic test (Fig. 1C, centre).

Traditionally, CSF or serum is applied onto tissue sections of mouse or rat brain. The antibodies bind specifically, e.g. to the NMDA receptor in the hippocampus (Fig. 1C, left).

Refined tests with even higher sensitivity are based on genetically modified cells which produce the target protein in high concentrations on their surface. These cell-based test methods have become the gold standard for the detection of anti-neuronal autoantibodies.

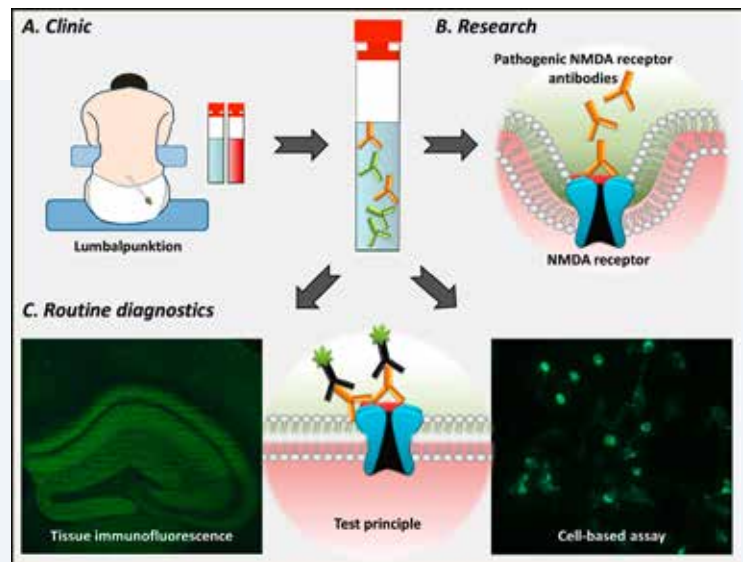
Each of these new antibodies is responsible for an independent disease picture. Exact information obtained by means of secured laboratory diagnostics not only helps to clearly allocate the clinical syndrome, but also indicates which type of individual immunotherapy should be chosen, enables



PD Dr. med. Harald Prüß

**Fig. 1: Diagnostics of pathogenic autoantibodies**

In suspected cases of autoimmune encephalitis, CSF and serum samples should be taken as a routine measure (A). In the sample, there are disease-associated antibodies (here NMDA receptor antibodies, yellow), as well as a number of further antibodies (green). Current research results were able to clearly show that NMDA receptor antibodies are directly pathogenic and lead to an internalisation of NMDA receptors in the nerve cells. The same pathogenic antibodies are also detected in routine diagnostics (C): The antibodies bind to their target antigen and are then made visible by a colour reaction with a fluorescence bound secondary antibody (centre). In this way, autoantibodies can be shown either on brain sections, through their characteristic binding pattern (left) – or through binding to genetically modified cells which express the corresponding target protein on the surface (right). Together with the typical clinical image, the positive antibody detection is considered proof for the respective encephalitis.



further prognosis and gives information on the likelihood of association with a tumour disease. The fact that cerebral MRI is inconspicuous in more than half of cases (even in severe cases of anti-NMDA receptor encephalitis) underlines the necessity of autoantibody determination for early diagnosis.

After anti-NMDA receptor encephalitis, encephalitis with LGI1 antibodies is the second most frequent autoimmune encephalitis. The LGI1 protein is linked with voltage-gated potassium channels (before grouped as VGKC antibodies) and protrudes from the nerve cell membrane. Therefore, the antibodies can bind perfectly to it. The patients have limbic encephalitis with memory and psychiatric disorders, epileptic seizures, and hyponatraemia. Older men are especially often affected. Short-term ipsi- or bilateral spasms in the face and of the arms, the so-called faciobrachial dystonic seizures (FBDS) are characteristic. The LGI1 antibodies must be detected with a cell-based test already at this stage in order to initiate immunotherapy and in this way stop the progression into bilateral hippocampal atrophy with extremely severe dementia-like memory disorders.

Antibodies against GABA receptors can also be produced and lead to the typical clinical disorders, often with severe epileptic seizures; in GABAA receptor encephalitis, even with therapy-refractory status. GABAB receptor encephalitis is frequently associated with small-cell lung carcinoma, which must then be specifically searched for in the case of positive antibodies. In glycine receptor encephalitis, there is excessive neuronal activity with startle reflex, sudden muscle spasms, generalised reflex progression, and cognitive deficits. Some cases of stiff-person syndrome are caused by glycine receptor antibodies. Encephalitis with DPPX antibodies was discovered only recently. Here, the immune reaction is directed against DPPX present in the brain as well as the intestine. Correspondingly, unclear diarrhoea with severe weight loss usually oc-

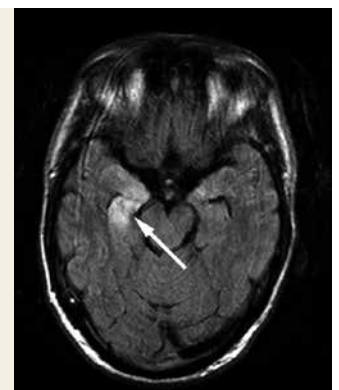
curs at the beginning of the disease. Only later, central symptoms such as tremor, epileptic seizures and myoclonia appear. Whilst patients with AMPA receptor encephalitis may suffer from epileptic seizures and memory disorders, a psychotic syndrome is the main symptom in most cases. Encephalitis with antibodies against the metabotropic glutamate receptor 5 (mGluR5) also starts with psychiatric symptoms. Changes in personality with emotional instability as well as subacute behavioural changes may correspondingly be confused with a psychiatric disease and only clearly diagnosed by determination of the respective autoantibodies.

It is generally recommended to analyse both CSF and serum, since in some patients the antibodies

*Fig. 2: Limbic encephalitis with mesiotemporal signal progression in the MRI (arrow)*

### Case report

Financial official Gerda H., 55 years old, had appeared changed since some days. She was easily irritated, seemed to forget things, had misplaced important files so they were nowhere to be found and came two hours late, which had never occurred before in all her years of work. During the lunch break, she fell to the floor, twitched with arms and legs and still seemed absent when the ambulance arrived. The first diagnosis was an epileptic attack, but the emergency physician was insecure due to the twitches of the left half of the face and the left arm which recurred every few minutes. In the hospital, a clear hyponatraemia of 122 mmol/l was diagnosed. The physicians in charge supposed an encephalitis caused by herpes virus. The rapid PCR test for herpes virus, however, was negative. In the cerebral MRI, an increased signal in the temporal lobe was visible in the right half (Fig. 2). In the search for anti-neuronal autoantibodies by means of cell-based assays, highly positive titers of antibodies against LGI1 were found in the serum. The patient was administered high doses of cortisone and a therapeutic apheresis, which led to a cessation of the faciobrachial dystonic seizures within a few days. Also the hyponatraemia, characteristic of LGI1 antibody encephalitis, normalised within the first week.



## Information

■ PD Dr. med. Harald Prüb  
German Center for Neurodegenerative Diseases (DZNE) Berlin, work group "Autoimmune Encephalopathies" and Charité – Universitätsmedizin Berlin, Department of Neurology with Experimental Neurology,  
Charitéplatz 1  
10117 Berlin

■ Counselling on Encephalitis & Paraneoplasias at Charité, Berlin:  
[https://neurologie.charite.de/leistungen/klinische\\_schwerpunkte/enzephalitis\\_und\\_paraneoplasien/](https://neurologie.charite.de/leistungen/klinische_schwerpunkte/enzephalitis_und_paraneoplasien/)

■ Patients with anti-NMDA receptor encephalitis and their relatives give a comprehensible overview of the disease, offer practical help and provide useful contacts:  
[www.anti-nmda-rezeptor-enzephalitis.de](http://www.anti-nmda-rezeptor-enzephalitis.de)

■ Work group on Autoimmune Encephalitides at the German Center for Neurodegenerative Diseases (DZNE) Berlin:  
<https://www.dzne.de/standorte/>

■ [berlin/forschergruppen/pruess.html](http://berlin/forschergruppen/pruess.html)  
The German Network for Research on Autoimmune Encephalitis provides expert advice and scientific cooperations: [www.generate-net.de](http://www.generate-net.de)

■ Determination of direct pathogenicity of monoclonal patient antibodies against NMDA receptors (Kreye et al. 2016, Brain 139 (Pt 10):2641–2652):  
<https://academic.oup.com/brain/article-lookup/doi/10.1093/brain/aww208>

■ EUROIMMUN AG  
Dr. Dominik Jäger  
D-23560 Lübeck Seekamp 31  
Telephone +49 (0) 45 1 / 58 55-0  
E-mail [euroimmun@euroimmun.de](mailto:euroimmun@euroimmun.de)

only occur in CSF (e.g. 15–20% of patients with anti-NMDA receptor encephalitis), while in other patients they are found in serum (e.g. in LGI1 antibody encephalitis). Moreover, it is useful to test for more than one target antigen (so-called panel diagnostics), since the underlying antibody cannot be clearly identified solely from the clinical image of an autoimmune encephalitis (Fig. 3). For instance, acute psychosis in a young woman may be caused by antibodies against neurexin-3α, GABA<sub>A</sub> receptors or the metabotropic glutamate receptor 5 (mGluR5) as well as the NMDA receptor antibodies.

In antibody diagnostics, it must be especially taken into account that the detection of an infectious pathogen does not by any means exclude an autoimmune encephalitis. According to current research results, the opposite is the case: as a consequence of herpes encephalitis, autoantibodies against NMDA receptors and further neuronal surface proteins may be secondarily formed. Our own investigations have shown that this applies to up to 20% of virus-caused encephalitides. In these cases, 3 to 8 weeks after encephalitis with herpes simplex virus I, a secondary deterioration occurs which had been misinterpreted until now as a relapse of the herpes encephalitis. However, it is actually an anti-NMDA receptor encephalitis with high antibody titers in CSF and serum. In adults, a psychosyndrome with memory disorders prevails in this phase, while in children mainly choreoathetotic movements occur relatively stereotypically. These postviral autoimmune encephalitides must be actively investigated in order to promptly start an efficient immunotherapy. This pathomechanism is not limited to HSV-1 and the formation of NMDA receptor antibodies. Therefore, a question of high clinical relevance must be asked: under which conditions may viruses lead to autoimmune encephalitis? Is it possible that already smaller pathogen-caused stimulations of the immune system suffice to cause the formation of autoantibodies and therewith mild clinical syndromes which until now have not been interpreted as autoimmune disorders, e.g. memory loss, fatigue, affective disorders or mild psychotic symptoms?

The development of the past years with newly discovered autoantibodies suggests that further antibodies will be identified as causative agents of diverse neuropsychiatric syndromes in the future. Therefore, in the clinical routine, it should be asked whether a new, yet undefined antibody might be present in the case of negative results in a cell-based assay. Analyses of CSF and serum should be performed in a research laboratory on brain sections in order to identify uncharacterised binding patterns on structures in the hippocampus, cerebellum or basal ganglia. In clinically plausible cases, even with negative results in both test procedures, an immunotherapy should be considered in order not to oversee treatable entities. The risks of the mainly well-tolerated first choice therapeutic options (steroids, therapeutic apheresis, intrave-

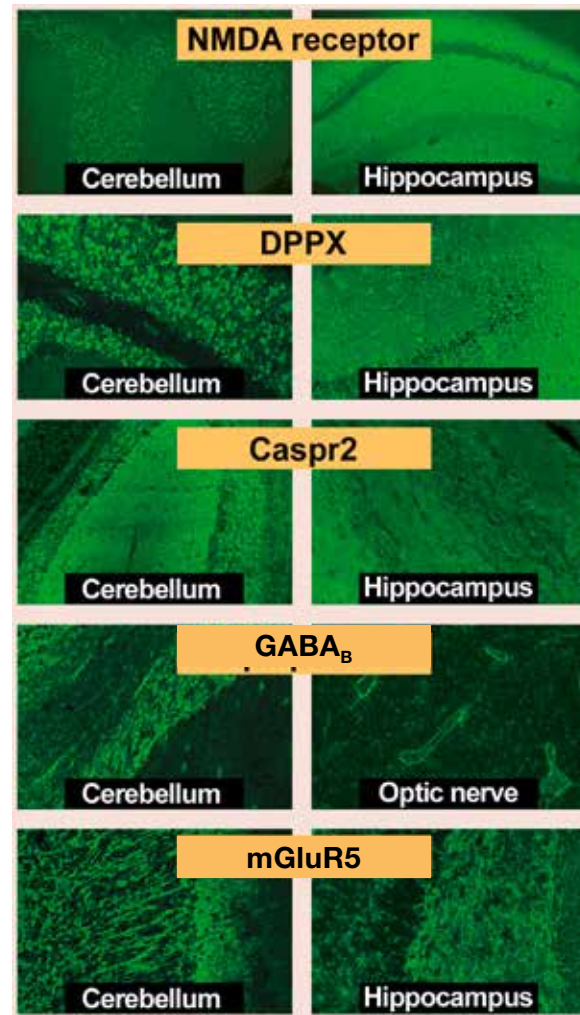


Fig. 3: Antibody findings in immunofluorescence (source: EUROIMMUN AG, Lübeck)

The spectrum of clinical symptoms results from an anatomical distribution of target antigens of the respective autoantibodies. Especially characteristic patterns of antibody binding are found in the hippocampus or cerebellum. The majority of antibodies binds to axons and neuronal surfaces and is therefore also referred to as neuropil antibody.

nous immunoglobulins, rituximab) are proportional when considering the risk-benefit ratio in the case of fulminant disease courses. These encompass amnesic-cognitive disorders, newly occurred psychoses, epileptic seizures or movement disorders, and especially inflammatory CSF syndromes without detection of an infectiological pathogen.

Literature available from the author