

Vertebrobasilar insufficiency caused by cervical aneurysmal bone cyst – Case report

*Benjamim Pessoa Vale¹, Eduardo Leitão de Almeida Lima²,
Ana Clara Mourão Barreto³, Luciano Arruda Macedo³*

Department of Neurosurgery and Hemodynamic at São Marcos Hospital; Federal University of Piauí (UFPI); Instituto de Neurociências, Teresina, PI, Brazil.

ABSTRACT

Aneurysmal bone cysts (ABC) are benign bone tumors of relatively rare occurrence. Most of the lesions occur at long bones, vertebrae and flat bones. However, the cervical vertebrae involvement is uncommon. Occasionally, the ABCs compress the spinal cord and nerve roots. Depending on the level of involvement and the extent of spinal cord compression, a wide variety of neurological symptoms and signs may be noted later, ranging from mild radiculopathy to complete paraplegia or tetraplegia. A case of aneurysmal bone cyst involving the second and third cervical vertebrae in a 15 years old patient, causing compression of the right vertebral artery and subsequent vertebrobasilar insufficiency is reported. We also discuss the clinical manifestations of the vertebrobasilar insufficiency, of the spinal compression, and the surgery treatment performed in this case.

KEYWORDS

Bone cysts aneurysmal, vertebral artery, vertebrobasilar insufficiency.

RESUMO

Insuficiência vertebrobasilar causada por cisto ósseo aneurismático cervical – Relato de caso
Cistos ósseos aneurismáticos são tumores ósseos benignos de ocorrência relativamente rara. A maior parte dessas lesões ocorre em ossos longos, nas vértebras e nos ossos planos. No entanto, o envolvimento das vértebras cervicais é incomum. Ocasionalmente, o cisto ósseo aneurismático pode comprimir a medula espinhal e as raízes nervosas. Dependendo do grau de envolvimento e extensão da compressão da medula espinhal, uma ampla variedade de sintomas e sinais neurológicos pode ser observada posteriormente, variando de radiculopatia suave a completa paraplegia ou tetraplegia. Relatamos um caso de cisto ósseo aneurismático envolvendo a segunda e a terceira vértebra cervical em um paciente de 15 anos, causando compressão da artéria vertebral direita e consequente insuficiência vertebrobasilar. Também discutimos as manifestações clínicas da insuficiência vertebrobasilar e da compressão espinhal e o tratamento cirúrgico realizado no caso em questão.

PALAVRAS-CHAVE

Cistos ósseos aneurismáticos, artéria vertebral, insuficiência vertebrobasilar.

1 Neurosurgeon and neuroradiologist at São Marcos Hospital and Instituto de Neurociências, Teresina, PI, Brazil.

2 Medicine student at Federal University of Piauí (UFPI), Teresina, PI, Brazil.

3 Medicine student at Faculdade Integral Diferencial (FACID), Teresina, PI, Brazil.

Introduction

Aneurysmal bone cysts (ABCs) are benign osteolytic and expansile lesions comprising thin-walled cysts with soft tissue septa inside filled with blood.^{1,2} They occur predominately in children and adolescents, with the peak incidence in those aged 16 years with slight female preponderance.³

The cervical vertebrae involvement is uncommon. When seen in this location, the lesion involves initially the posterior arch and pedicles, with bone destruction and cortical expansion.^{4,5}

Vertebrobasilar insufficiency may be caused by many types of lesions. However intrinsic lesions, such as atherosclerosis, are usually held responsible. Extrinsic lesions are less common.⁶ Vertebrobasilar insufficiency may cause as symptoms dizziness, vertigo, diplopia, ataxia, dysarthria, visual disturbance, numbness, and motor weakness due to transient ischemia of the brainstem or cerebellum.⁷

The treatment of ABCs of the spine presents unique challenges due to the risk of vertebral destabilization, pathological fracture, vertebral body collapse and neurological compromise.⁸

Case report

A 15 year-old boy presented pain in the right cervical region with duration of 15 days, which began after abrupt deceleration of the neck in a soccer match. The pain became intense with movement and palpation of the neck and decreased with rest. The initial suspicion was stiff neck, but there was no improvement with the use of painkillers and muscle relaxants. Endoscopic examinations were performed and biochemical investigation, both with no alteration. After evaluation of head and neck the patient was taken to the Department of Neurosurgery at São Marcos Hospital for neurological examination.

The patient developed right dimidius weakness and change in level of consciousness. Physical examination revealed palpable nodules in the right cervical region and pain with limited range of motion in lateral rotation, flexion and extension of the neck. Neurological examination showed right motor deficit, with no signs of low cranial nerve involvement. The Computed tomography (CT) scans revealed an expansive osteolytic lesion in C2 and C3, with destruction on its right pedicles and direct compression of the spinal cord (Figure 1). Cerebral angiography revealed a vascularized lesion in the right cervical region and extraluminal compression of right vertebral artery (VA)

with significant stenosis and distal hypoflow (Figure 2). Cervical lymph node biopsy and paravertebral cyst capsule revealed histopathological diagnosis compatible with aneurysmal bone cyst.

Initial treatment consisted of right vertebral artery angioplasty with stent and tumor embolization with particles of poly-vinyl-alcohol (PVA) (Figures 3 and 4). Based on the location of the lesion, anterior surgical resection with reconstruction and internal stabilization was considered the best approach. This process consisted of en bloc total resection of the bone injury at C2-C3

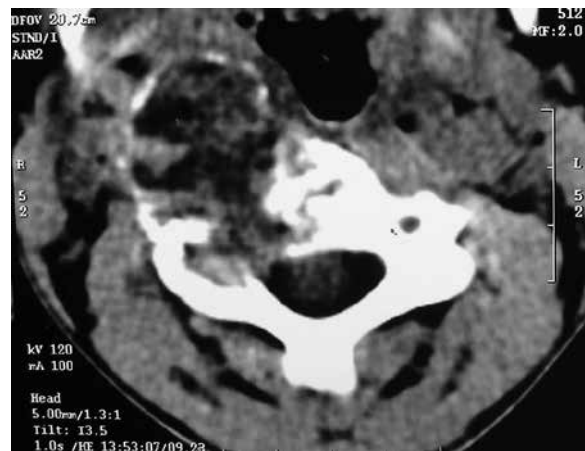


Figure 1 – Computed tomography scan of the cervical spine revealing an expansive osteolytic lesion in C3, with destruction on its right pedicle and direct compression of the spinal cord.

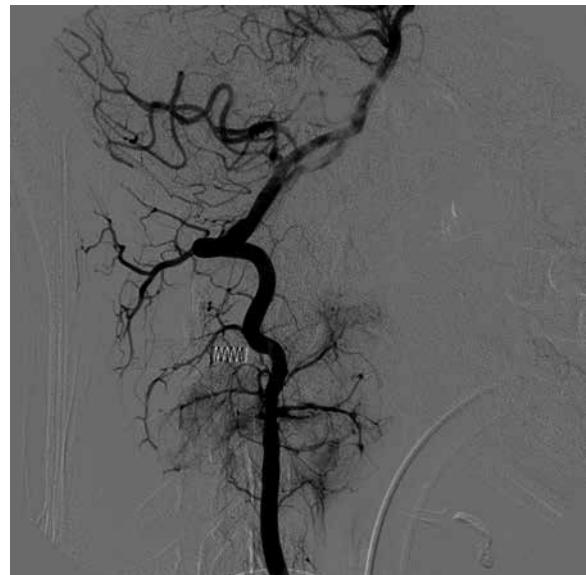

Figure 2 – Cerebral angiography revealed a vascularized lesion in the right cervical region and extraluminal compression of right vertebral artery. Observe the main feeding arteries tumor and the tumoral blush.

and right vertebral artery levels, followed by anterior instrumentation of the cervical spine with bone plates and screws, performing cervical fusion of C2-C4. The radiographic image confirmed the proper placement of instruments in the cervical region (Figure 5). The patient was neurologically intact after surgery and his recovery progressed uneventfully. In 24 months of follow-up, the patient had no pain in the neck and normal movement of cervical region, without right motor deficit, absence of cervical spine instability and no recurrence of the tumor.

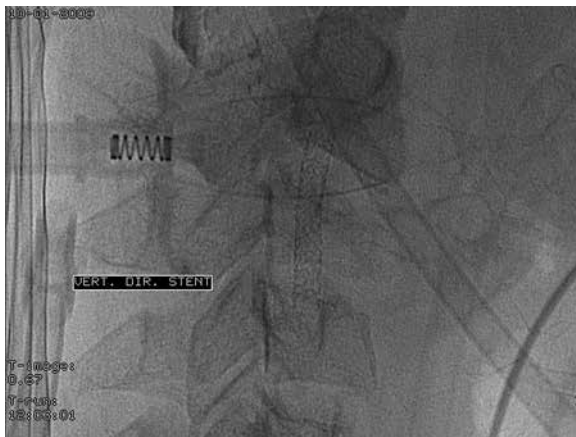

Figure 3 – Angiographic image showing stent implanted in the right vertebral artery, before the tumor resection.

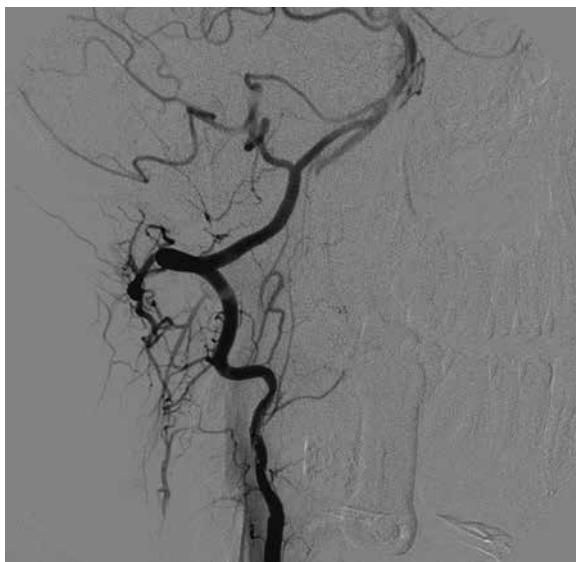


Figure 4 – Right vertebral artery angiography after selective lesion's arterial embolization, showing considerable reduction in tumor vasculature.

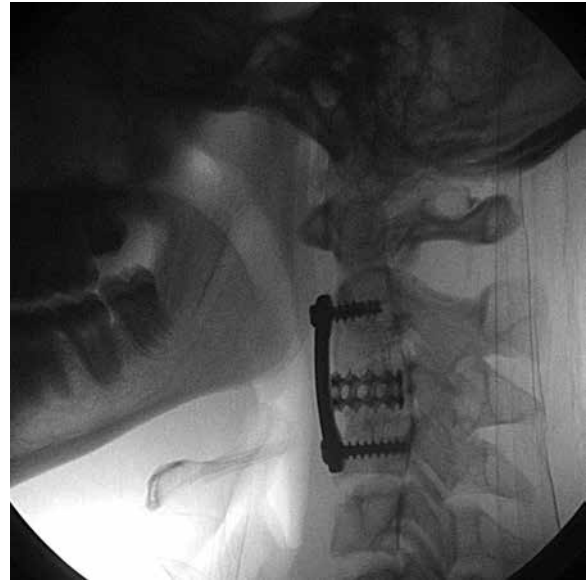


Figure 5 – Radiographic image presenting the anterior instrumentation of the cervical spine with C2-C4 fusion.

Discussion

Vertebrobasilar insufficiency is a clinical condition presenting symptoms such as dizziness, vertigo, diplopia, ataxia, dysarthria, visual disturbance, numbness, and motor weakness due to transient ischemia of the brainstem or cerebellum.⁷ It is usually caused by intrinsic lesions of the VA, such as atherosclerosis and thromboembolism. On the other hand, compression of the VA by osteophytes, tumors, or other musculoskeletal factors can also cause this syndrome, which could be induced or exacerbated with head rotation toward the compressed side.^{9,10} In our case, the vertebrobasilar insufficiency was caused by extrinsic compression of the right vertebral artery by an aneurysmal bone cyst, located in C2 and C3 regions.

ABCs are benign and highly vascular lesions, characterized by expansile blood-filled cystic cavities, comprising thin-walled cysts with soft tissue septa inside.¹¹ ABCs are relatively rare lesions that occur more commonly among patients in the first and second decades, mainly in women.⁴ It is located on the spine in 6%-20% of cases. The posterior elements and the pedicles are usually affected first, and in 60%-70% of cases the lesion extends into the vertebral body.¹²

The cervical vertebrae involvement is uncommon. When seen in this location, the lesion involves initially the posterior arch and pedicles, with bone destruction and cortical expansion. Occasionally, the ABCs compress the spinal cord and nerve roots.^{4,5} In the present case, there was an osteolytic lesion

with destruction of C2 and C3 pedicles, with tumor expansion and compression of the right vertebral artery, which justified the blood hypoflow diagnosed in cerebral angiography. Besides bone destruction, tumor caused spine cord compression, provoking right motor deficits.

A typical magnetic resonance imaging (MRI) of an ABC depicts tumor masses with smooth margins and osseous destruction. Inside the tumor there are multiple cysts, commonly with fluid levels.³ Computed tomography (CT) typically reveals as a characteristic soap-bubble appearance, which represents a ballooning, multilocular lytic lesion. Common findings include pathologic fracture or partial vertebral body collapse (or even sometimes complete). Preoperative CT imaging is helpful for assessing pedicle and vertebral body integrities in anticipation of instrumented fusion.¹² In our case we can observe the destruction of C2 and C3 pedicles in the images of CT, but with no vertebral body collapse.

The differential diagnosis must rule out other benign spine tumors and malignant tumors. In increasing order of frequency, bone tumors in children are eosinophilic granulomas, osteblastomas, and osteoid osteoma.¹³ Conventional treatment has been directed at the surgical removal of either the entire lesion or as much of it as possible. Recurrence is seen in 10%-44% of cases, with 90% recurring within two years.⁷ Selective arterial embolization can be considered as the primary isolated treatment or as adjuvant therapy for reducing intraoperative bleeding. However, the most difficult of this option is that the feeding artery cannot always be identified.¹⁴ Inadequate embolization of the feeder may result in recurrence or residual lesion. Moreover, in consideration of spine stabilization and neurologic decompression, embolization alone seems not feasible.¹ Cases of mortality and serious complications also have been reported.¹⁴ Lesions are usually treated with curettage and bone grafting. More aggressive treatment reserved for large lesions, or those compressing the spinal cord or nerve roots, and for recurrences. Stabilization with osteosynthesis is usually performed next. Nevertheless, in young patients it is important to preserve the spine alignment and permit harmonious development until growth terminates.¹² En bloc total resection is associated with the lowest recurrence rate, although surgical resection may not be possible without significant risk and morbidity. A combined posterior and anterior approach with stabilization may be required.¹⁵ In our case, we opted for en bloc resection of the lesion with anterior approach and spinal fusion with anterior cervical spine instrumentation (plate and screws). Before surgical resection, it was performed a right vertebral artery angioplasty with stent placement,

to reconstruct the blood flow to the vertebrobasilar system. We opted not to occlude the vertebral artery through embolization due vertebrobasilar insufficiency signs presented by the patient throughout the disease.

Conclusion

ABCs of cervical spine are rare injuries, but can present rapid expansion, pain, spinal compression and pathologic fracture. Treatment is challenging because the tumor shows aggressive behavior causing risk of destabilization of the spine. Complete resection of the lesion is the treatment of choice, especially when the patient has a neurologic deficit. In extensive lesions with involvement of the vertebral artery preoperative angiography may be necessary to evaluate the occlusion possibility of that artery. A suitable instrumentation is important for prevention of unstable cervical spine after resection of the lesion.

Competing interests

The authors declare no conflict of interest.

References

1. Boriani S, De Iure F, Campanacci L, Gasbarrini A, Bandiera S, Biagini R, et al. Aneurysmal bone cyst of the mobile spine: report on 41 cases. *Spine (Phila Pa 1976)*. 2001;26(1):27-35.
2. Levy WM, Miller AS, Bonakdarpour A, Aegerter E. Aneurysmal bone cyst secondary to other osseous lesions. Report of 57 cases. *Am J Clin Pathol*. 1975;63(1):1-8.
3. Dahlin DC, McLeod RA. Aneurysmal bone cyst and other nonneoplastic conditions. *Skeletal Radiol*. 1982;8(4):243-50.
4. Mankin HJ, Hornicek FJ, Ortiz-Cruz E, Villafuerte J, Gebhardt MC. Aneurysmal bone cyst: a review of 150 patients. *J Clin Oncol*. 2005;23(27):6756-62.
5. Garg S, Mehta S, Dormans JP. Modern surgical treatment of primary aneurysmal bone cyst of the spine in children and adolescents. *J Pediatr Orthop*. 2005;25(3):387-92.
6. Takeuchi S, Kawaguchi T, Nakatani M, Isu T. Hemorrhagic infarction originating from vertebral artery stenosis caused by an osteophyte at the C5 superior articular process. *Neurol Med Chir (Tokyo)*. 2009;49(3):114-6.
7. Kransdorf MJ, Sweet DE. Aneurysmal bone cyst: concept, controversy, clinical presentation, and imaging. *AJR Am J Roentgenol*. 1995;164(3):573-80.
8. Codd PJ, Riesenburger RI, Klimo P Jr, Slotkin JR, Smith ER. *Vertebra plana* due to an aneurysmal bone cyst of the

- lumbar spine. Case report and review of the literature. *J Neurosurg.* 2006;105(Suppl 6):490-5.
9. Bakay L, Leslie EV. Surgical treatment of vertebral artery insufficiency caused by cervical spondylosis. *J Neurosurg.* 1965;23(6):596-602.
 10. George B, Laurian C. Impairment of vertebral artery flow caused by extrinsic lesions. *Neurosurgery.* 1989;24(2):206-14.
 11. Jaffe H, Lichtenstein L. Solitary unicameral bone cyst with emphasis on the roentgen picture, the pathologic appearance, and the pathogenesis. *Arch Surg.* 1942;44:1004-25.
 12. Benayada B, Allali N, Sefiani S, Arkha Y, Dafiri R. Aneurysmal bone cyst: a rare cause of medullary compression and painful scoliosis in children. *Presse Med.* 2010;39(7-8):837-40.
 13. Fender P, Clavert JM, Sengler J, Soutter JW, Ligier JN, Perrin S. Scoliose douloureuse du petit enfant: à propos d'un cas de kyste anévrysmal osseux lombaire (corps de L4 et arc postérieur). *Ann Readapt Med Phys.* 1995;38:443-6.
 14. Fay LY, Wu JC, Huang WC, Shih YH, Cheng H. One-stage posterior resection is feasible for a holovertebral aneurysmal bone cyst of the axis: a case report and literature review. *Surg Neurol.* 2009;7(Suppl 2):80-5.
 15. Peraud A, Drake JM, Armstrong D, Hedden D, Babyn P, Wilson G. Fatal ethibloc embolization of vertebrobasilar system following percutaneous injection into aneurysmal bone cyst of the second cervical vertebra. *AJNR Am J Neuroradiol.* 2004;25(6):1116-20.

Correspondence address

Eduardo Leitão de Almeida Lima
 Av. Ferroviária, 2872, Ilhotas
 64014-080 – Teresina, Piauí, Brazil
 Telephone: (55 86) 8828-5118
 E-mail: reialima@hotmail.com