

Familial adenomatous polyposis associated with gastrointestinal stromal tumor: Report of a case

Cumhur İbrahim BAŞSORGUN¹, İrem Hicran ÖZBUDAK¹, Gülgün ERDOĞAN¹, Gülsüm Özlem ELPEK¹, Okan ERDOĞAN², Tekinalp GELEN¹

Departments of ¹Pathology and ²General Surgery, Akdeniz University School of Medicine, Antalya

Desmoid tumors are one of the most common extracolonic manifestations of the familial adenomatous polyposis. However, other soft tissue tumors are seen rarely in patients with familial adenomatous polyposis, including gastrointestinal stromal tumor. There is only one case reported in the literature. We describe a 29-year-old female who developed ileal malignant gastrointestinal stromal tumor 15 months after proctocolectomy for familial adenomatous polyposis, with a review of the literature focusing on sarcomas arising in this inherited disease. We suggest that the rare occurrence of gastrointestinal stromal tumor in familial adenomatous polyposis does not exclude their consideration in the differential diagnosis of extracolonic manifestations of the disease.

Key words: Familial adenomatous polyposis, soft tissue tumors, gastrointestinal stromal tumor, desmoid tumor

Gastrointestinal stromal tümör ile birlikte familial adenomatöz polipozis: Olgu sunumu

Desmoid tümör, famiyal adenomatöz polipozis ile beraber olan en yaygın ekstrakolonik tutulumdur. Famiyal adenomatöz polipozis ile beraber yumuşak doku tümörleri özellikle gastrointestinal stromal tümör nadir görülür. Literatür araştırmasında sunulmuş bir olgu saptanmıştır. Bizim tanımladığımız olgu 29 yaşında, ileal malign gastrointestinal stromal tümör tanısı konduktan 15 ay sonra famiyal adenomatöz polipozis nedeniyle proktokolektomi olan kadın hastadır. Sunumuzda literatür eşliğinde ailesel olgular ile sarkomların birlikteliğini araştırıp derledik. Famiyal adenomatöz polipozis ile beraber gastrointestinal stromal tümör birlikteliği nadir görülse bile ekstrakolonik yayılımların ayrıntı tanısında dışlanmadan dikkate alınması gerekmektedir.

Anahtar kelimeler: Famiyal adenomatöz polipozis, yumuşak doku tümörleri, gastrointestinal stromal tümör, desmoid tümör

INTRODUCTION

Familial adenomatous polyposis (FAP) is an autosomal dominant, hereditary syndrome that is characterized by the presence of hundreds to thousands of colorectal adenomas, which, if not surgically treated, develop into colorectal cancer in all cases. FAP is caused by germline mutations of the adenomatous polyposis coli (APC), which has been defined as a tumor suppressor gene and is basic for the Wnt signaling pathway (1,2). Therefore, up-regulation of Wnt pathways, due to APC gene mutations in all cells, is not only responsible for the development of colorectal adenomas and sub-

sequent malignant transformation, but also determines the occurrence of benign and malignant tumors in other sites (2). Indeed, an association of FAP with extracolonic manifestations (ECMs) has been described extensively (2,3). FAP can be combined with soft tissue tumors. Among these, desmoid tumors (in particular, within the abdominal cavity and retroperitoneum) are one of the most common ECMs of the disease, and they contribute significantly to morbidity and mortality rates (4). However, sarcoma is seen rarely in patients with FAP (6-10).

Address for correspondence: Cumhur İBRAHİM BAŞSORGUN
Department of Pathology,
Akdeniz University School of Medicine, Antalya, Turkey
E-mail: drbassorgun@gmail.com

Manuscript received: 25.11.2010 **Accepted:** 26.01.2011

Turk J Gastroenterol 2012; 23 (3): 262-266
doi: 10.4318/tjg.2012.0289

Gastrointestinal stromal tumors (GISTs) are the most common primary mesenchymal neoplasms of the gastrointestinal system. They occur mostly as sporadic solitary lesions and only rarely coexist with other neoplasms or appear as a part of a multi-neoplastic disease (5). The occurrence of GIST in the context of FAP is extremely rare, with only one case reported in the literature (10).

Herein, we report a rare case of GIST that involved the ileum, presenting 15 months after proctocolectomy for FAP, with a review of the literature focusing on sarcomas arising in this inherited disease. We also discuss mechanisms for the development of GIST in FAP.

CASE REPORT

The patient was a 29-year-old female with a nine-month history of abdominal distension, constipation, fever, and intermittent rectal bleeding. On the physical examination, her abdomen was slightly distended and non-tender, and bowel sounds were hypoactive. The complete blood count was significant for anemia; tumor markers were not elevated. On colonoscopy, she was found to have hundreds of polyps in the colon and rectum, and two of them were excised. Endoscopic examination of the upper gastrointestinal system was normal. An abdominal computed tomography (CT) did not demonstrate any neoplasm. Her previous medical history inclu-

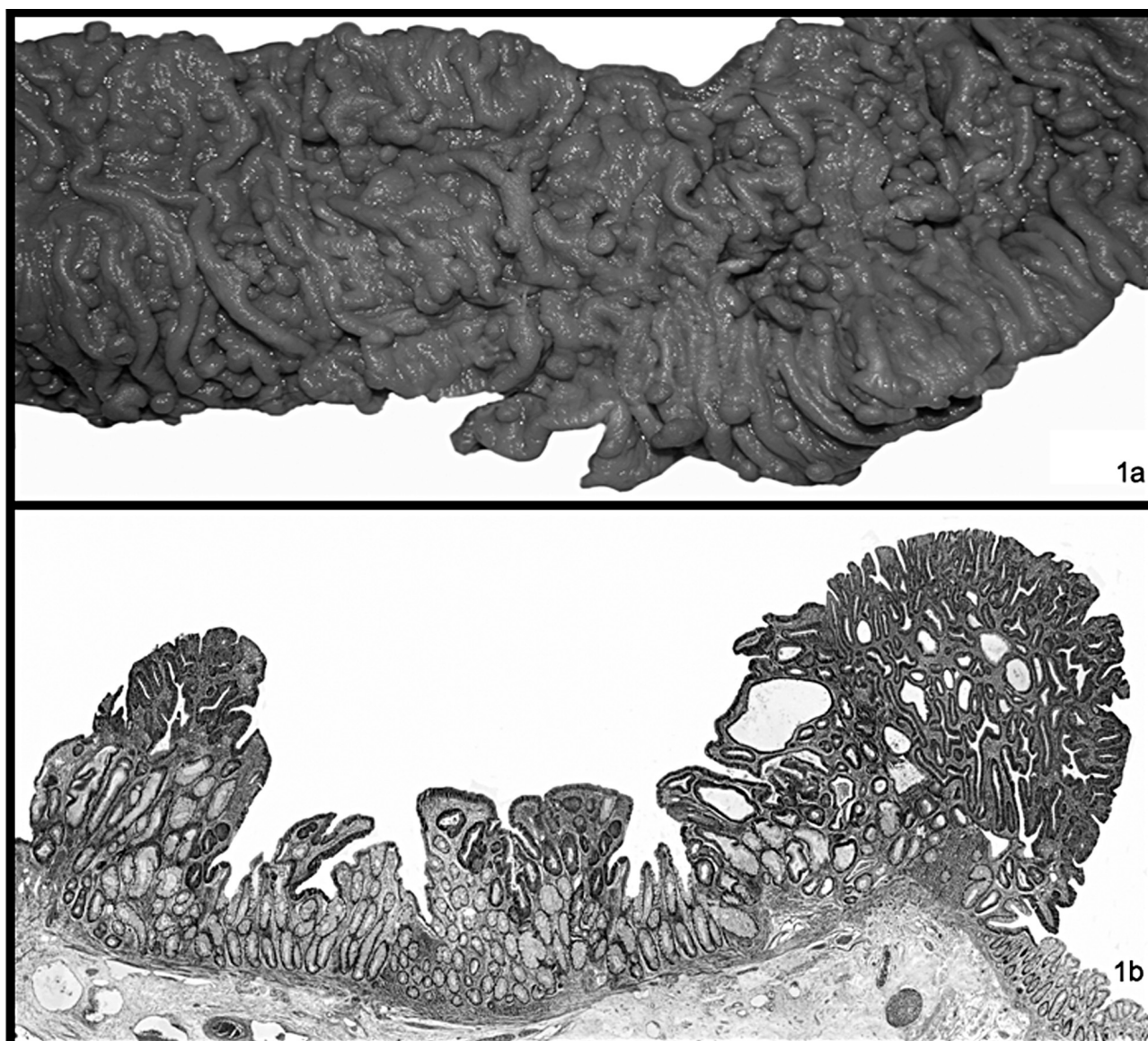


Figure 1a. Macroscopic findings: A number of small polyps are present in the colon. **1b.** Adenomatous change developing within a small polyp.

ded a genetic analysis report in 2000 describing a deletion of the APC gene on chromosome 5q. From her familial medical history, there were three victims of FAP on her father's side (father, uncle and grandmother). All died from colon cancer. The histopathological examination of resected polyps demonstrated tubular adenomas with high-grade dysplasia. A restorative proctocolectomy with ileal pouch anal anastomosis was performed. Pathologic examination revealed the presence of hundreds of small polyps (ranges <1 mm and 2 cm) (Figure 1 a). They were either sessile or pedunculated and were distributed along the whole mucosa. Microscopically, most of them were identified as tubular adenoma with high- grade dysplasia. The presence of microadenomas was also observed (Figure 1b). The patient had an uneventful postoperative course and was discharged on the 10th postoperative day. Fifteen months later, she admitted to the Department of Surgery with abdominal distension and pain. CT scan showed an intraabdominal nodular mass, located at the wall of the ileum. The patient

underwent laparotomy with a preoperative diagnosis of desmoid tumor. A small bowel resection with a complete removal of the mass was performed and exploration of the abdomen revealed no additional lesion. In the surgical material, there was a segment of the ileum, and a juxtaposed nodular tumor, measuring 11 x 13 x 13 cm. On cut section, this gray-white transmural tumor showed a relatively well-defined but unencapsulated border. Necrosis and hemorrhage was observed (Figure 2a). Histologically, the tumor consisted of spindle and ovoid-shaped mesenchymal cells with eosinophilic cytoplasm and single elongated nuclei (Figure 2b). A moderate level of pleomorphism, cellularity and mitotic activity (5 mitoses per 50 high power fields [HPF]) were present (Figure 2c). In the immunohistochemical analysis, CD-117 was strongly expressed in the cytoplasm of tumor cells (Figure 2d). CD34 was also positive (Figure 2e). However, smooth muscle actin (SMA), desmin, S100, and β -catenin were negative, supporting the diagnosis of GIST (Figure 2).

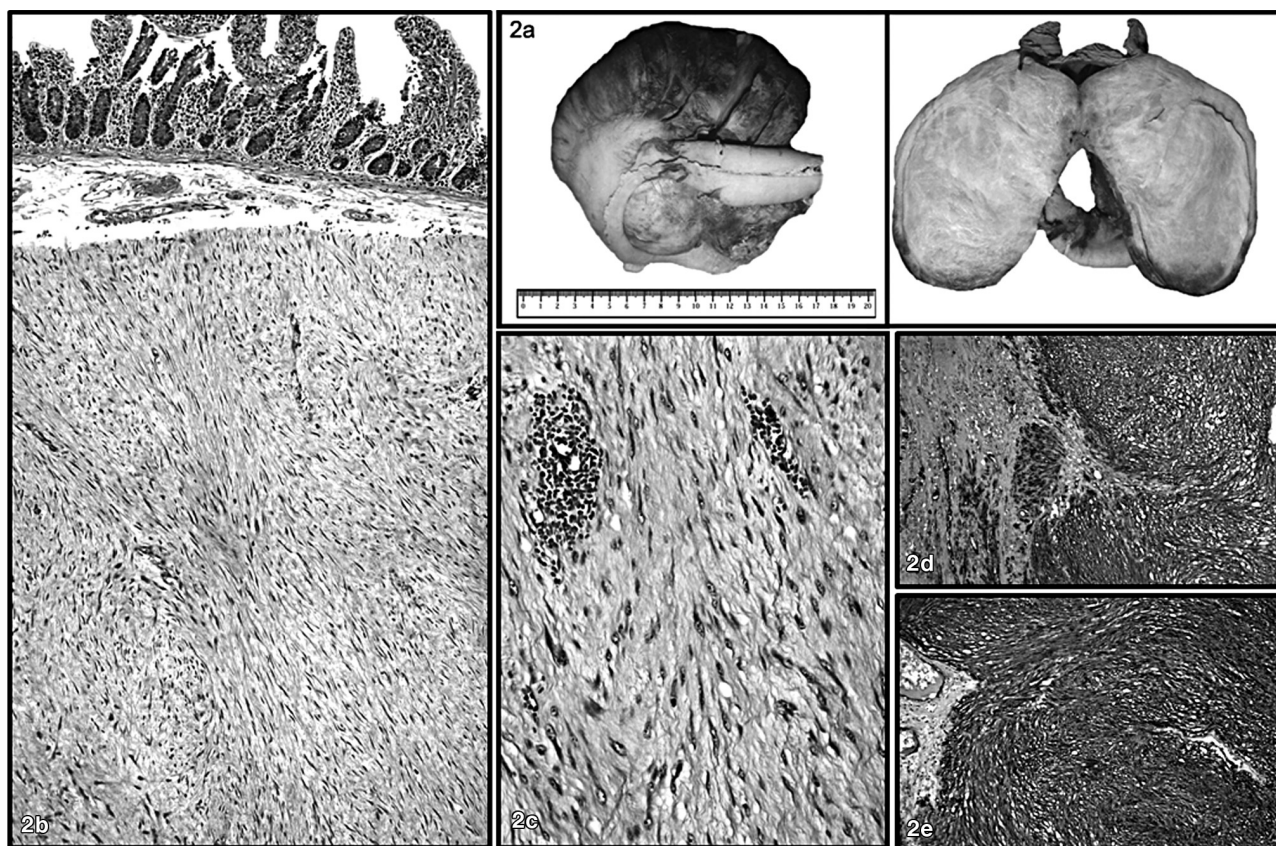


Figure 2a. Macroscopic findings: The resected small bowel with a well- circumscribed firm mass in the mesenteric adipose tissue, which exhibits an expanding growth pattern. The tumor has a tan-gray appearance on cut surface, and infiltrates the bowel wall. **2b, 2c.** The tumoral lesion consisted of spindle cells growing in sweeping fascicles, with eosinophilic cytoplasm and sometimes plump nuclei (**2b**, H&E 40x, **2c**, H&E 400x). **2d.** Most of the tumor cells show immunoreactivity for c-kit (CD117) in their cytoplasm (**2d**, IHC 100x). **2e.** Immunohistochemical stain for CD34 is also present in the tumor (**2e**, IHC 200x).

Table 1. Clinical findings of previously reported FAP cases associated with sarcomas

Reference	Case	Age (years)	Gender	Localization	Pathological Diagnosis
Armstrong et al.	1	16	F	Orbita	Rhabdomyosarcoma
Uzoaru et al.	1	14	M	Kidney	Clear cell sarcoma
Penel et al.	1	38	M	Face	Undifferentiated sarcoma
Jannasch et al.	1	24	M	Retroperitoneum	Fibromyxosarcoma
Moschos et al.	1	30	M	Mesentery	GIST
Present case	1	34	F	Ileum	GIST

FAP: Familial adenomatous polyposis. GIST: Gastrointestinal stromal tumor.

DISCUSSION

Familial adenomatous polyposis (FAP) is a rare hereditary cancer syndrome, which is often associated with ECMs (over 70%) (3). Although most ECMs have little clinical significance, some lesions can cause serious complications and even lead to death (2,3). In FAP, as is typical with hereditary cancer syndromes, there is a high risk of malignancies, including thyroid cancer, hepatoblastoma, medulloblastoma, and pancreatic carcinoma (2). However, FAP-associated sarcomas have been reported rarely (6-10). The present case involved a 29-year-old female with metachronous GIST occurring 15 months after prophylactic proctocolectomy for FAP. Our patient is older than the previously reported sarcomas cases (mean: 26.16 years) and is in contrast to the frequent male predilection of these tumors (F/M: 1/5), suggesting that sarcomas in the background of FAP are not limited only to younger age groups and men (Table 1). As in the present case, sarcomas in the context of FAP occurred as solitary lesions. They did not demonstrate any preferential location and they are in different histological subtypes. In FAP, a simultaneous occurrence of GIST was described previously by Moschos et al. (10) in a 30-year-old man. However, in our patient, GIST occurred 15 months following proctocolectomy, demonstrating that although rare, this tumor might be taken into consideration during the follow-up for ECMs of FAP.

Over the past decades, it has also been proposed that the specific area of the APC gene that is mutated might determine the ECMs encountered in FAP (2,3). However, it has been demonstrated recently that all ECMs can be associated with mutations anywhere in the APC gene, except for congenital hypertrophy of the retinal pigment epithelium (restricted to codon 311-1444) and for desmoids (generally related to mutations beyond codon 1395) (3). Regarding GIST, the rarity of these tu-

mors in FAP (there are only a few cases: our case and the case presented by Moschos et al. [10]) necessitates new cases to determine the exact role of the mutation site of the APC gene in the development of these tumors.

A GIST occurs mostly as a sporadic isolated lesion, with a mean patient age of 55-65 years (1,5). These tumors are only rarely associated with other neoplasms or may occur as part of a multi-neoplastic disease as in the setting of neurofibromatosis 1, Carney's triad and type 1 multiple endocrine neoplasia (MEN) (5). The role of c-kit or PDGFRA mutations in the pathogenesis of GIST is well documented. However, their role in the pathogenesis of GIST developing in disease syndromes is controversial. In patients with Carney's triad as well as in patients with NF-1, it is observed that the development of GIST is associated with different mutations from those in sporadic GIST (5). At present, it is not known if GIST occurring in the context of FAP had different mutations than those of sporadic GIST. Further molecular studies with a large number of cases are required to demonstrate the pathogenesis of GIST developing in patients with FAP.

In conclusion, the present case is the second such case of GIST occurring in the context of FAP, supporting their presence in this disease, and the first to be found metachronously after proctocolectomy, providing further evidence for their clinical presentation as ECMs of FAP. For these reasons, the rare occurrence of GIST in FAP does not exclude their consideration in the differential diagnosis of ECMs of the disease.

We suggest that as more cases are reported, the relation between the site of mutation of the APC gene and GIST development as well as the exact pathogenesis of GIST in FAP patients will be shown in more detail.

REFERENCES

1. Cohen MM. Molecular dimensions of gastrointestinal tumors: some thoughts for digestion. *Am J Med Gen* 2003; 122A: 303-14.
2. Cetta F, Dharmo A. Inherited multitemporal syndromes including colorectal carcinoma. *Surg Oncol* 2007; 16: S17-S23.
3. Nieuwenhuis MH, Vasen HFA. Correlations between mutation site in APC and phenotype of familial adenomatous polyposis (FAP): a review of the literature. *Crit Rev Oncol Hematol* 2007; 61: 153-61.
4. Sturt NJ, Clark SK. Current ideas in desmoid tumors. *Fam Cancer* 2006; 5: 275-85.
5. Lukasz L, Zielinska-Pajak E, Pajak J, et al. Coexistence of gastrointestinal tumors with other neoplasms. *J Gastroenterol* 2007; 42: 641-9.
6. Armstrong SJ, Duncan AW, Mott MG. Rhabdomyosarcoma associated with familial adenomatous polyposis. *Pediatr Radiol* 1991; 21: 445-6.
7. Uzoaru I, Podbielski FJ, Chou P, et al. Familial adenomatous polyposis coli and clear cell sarcoma of the kidney. *Pediatr Pathol* 1993; 13: 13-41.
8. Penel N, Berthon C, Kara A, et al. [Association soft tissue sarcoma and familial adenomatous polyposis: a case-report]. *Rev Med Interne* 2005; 26: 596-7.
9. Jannasch O, Dombrowski F, Lippert H, Meyer F. Rare coincidence of familial adenomatous polyposis and a retroperitoneal fibromyxoid sarcoma: report of a case. *Dis Colon Rectum* 2008; 51: 477-81.
10. Moschos J, Tzilves D, Paikos D, et al. Large mesenteric gastrointestinal stromal tumor in a patient with familial adenomatous polyposis syndrome. *Wien Klin Wochenschr* 2006; 118: 355-7.